

HEPATOPROTECTIVE EFFECT OF TURMERIC ON THE STRUCTURAL INTEGRITY OF LIVER OF PUBERTAL RABBITS EXPOSED TO ACUTE ULTRAVIOLET RADIATION

Olatunji I.O* Emmanuel T.O#

*Department of Physiology, College of Medicine, University of Lagos Idi-Araba. #Department of Physiology, College of medicine Bowen University Iwo Osun State

Abstract: Background: One of the non-ionizing radiations in electromagnetic spectrum is ultraviolet (UV) radiation. Studies have shown that UV radiation causes the generation of reactive oxygen species and subsequent radical formation as well as direct damage to cell macromolecule. This study was undertaken to assess the hepatoprotective effect of turmeric on rabbits acutely exposed to ultraviolet radiation. **Methods:** Forty rabbits between the ages of 18-20 weeks were weight balanced into five groups, and randomly allocated to five (5) treatments: A, B, C, D, E. Group A (ttr): fed organic feed without turmeric and not radiated, Group B (ttR): fed organic feed without turmeric inclusion before they were radiated. Group C (TTr): fed diet supplemented with 2% turmeric as its constituent but not radiated. Group D (TTR): fed organic feed supplemented with 2% turmeric before they were radiated. Group E (ttr) is the control: fed commercial feed along with forage throughout the experiment and not radiated. The irradiation was done for 10 minutes period for ten consecutive days. The liver of the 40 rabbits were harvested and the histology of the liver section was done. **Results:** The histological studies revealed that the groups radiated have structural differences from the control. Liver section in Group B shows that there was hepatic necrosis and degeneration of cells. There was also a dense portal infiltration with lobular extension, confirming the damaging effect of UV radiation. The liver damage was mild in Group D, indicating the hepatoprotective properties of turmeric. The histology of rabbit in Group A revealed ova cells of hepatocyte, which are progenitor cell that are involved in the regeneration process. Rabbits in Group C as well as the control Group E, showed normal histological appearance.

Conclusion: It was concluded that UV radiation has detrimental effect on the liver and organic turmeric has hepatoprotective properties.

Key Words: liver histology, turmeric, UV radiation.

Author for correspondence: Mr Olatunji Idowu. Department of Physiology, College of Medicine, University of Lagos. 08066064536. e- mail: olatunjiidowu00@gmail.com

Introduction: Turmeric (*Curcuma longa*) is a plant of Zingiberaceae family mostly recognised as ginger family. According to Daod and Aslam, turmeric is often used as a colouring material for medicines besides its medicinal and pharmacological qualities¹. Also, an orange-yellow component of turmeric "curcumin" is a polyphenol natural product isolated from the rhizome of the plant *curcuma longa*. Curcumin has been used in some medicinal preparation for centuries or as a food-colouring agent. It was extensively used for treatment of swelling and sprains caused by injury in old Hindu medicine².

However, one of the non-ionizing radiations in the electromagnetic spectrum is ultraviolet (UV) radiation with wavelengths from 100nm to 400nm. It was discovered by Kelly *et al.*, that the most artificial sources of UV irradiation of the skin causes a systematic immunosuppression in both mice and

humans³. It was reported by Halliday, that much is still unknown about the mechanism that controls systemic immune following UV radiation⁴. It was evident from a study that was carried out by Kvam and Tyrrell, that UV radiation causes the generation of reactive oxygen species and subsequent radical formation as well as direct damage to cell macromolecules⁵. Meanwhile, in human the most pronounced effect of prolonged UV exposure is development of cancer of the skin⁶.

Additionally, the liver is the largest gland and the main metabolic organ of the body with diverse functions. The organ is involved in metabolizing and detoxifying varieties of endogenous as well as exogenous compounds, rendering them hydrophilic and thus affecting their activity and potency⁷.

This study was undertaken since fewer researches have been done on assessing hepatoprotective

effect of turmeric on rabbit acutely exposed to ultraviolet radiation.

The aim of this study is to determine the effect of organic turmeric supplemented diet on the structural integrity of the liver of pubertal rabbits acutely exposed to ultraviolet radiation and the research objectives are to determine the effect of UV radiation on histopathology of the liver and to verify the hepatoprotective effects of turmeric.

Materials and Methods:

Experimental site: This experiment was carried out at the rabbitary unit of the teaching and research farm, Ladoke Akintola University of Technology (LAUTECH) Ogbomoso Nigeria. Ogbomoso is located on longitude 4 degree 15' east at the Greenwich meridian and latitude 8 degree 15' north at the equatorial. The altitude is between 300m and 600m above the sea level while the mean temperature and annual rainfall are 27^o celcius and 1247mm respectively.

Housing and animal management: Three wooden cages with 24 hutches in each cage were used for this experiment. The dimension of the hutches was 51cm length by 62cm breath, large enough to contain 5 rabbits of age 8-10 weeks at a time. However, two rabbits were placed in each hutch. The hutches were cleaned regularly. The whole rabbitary and the hutches were thoroughly disinfected, and the rabbits were moved in. The does and the bucks were separated so as to make the environment free from germs and deadly pathogens that may attack the rabbits. All routine management practices were observed and morphological parameters were obtained every week from the commencement of the experiment.

Animal collection: Forty (40) weaned rabbits with age range between 4-6 weeks were obtained from Institutional Animal Facilities and were allowed to acclimatize for 4 weeks. The rabbits were maintained on a concentrate diet containing 18% CP and 2500 Kcal/kg ME along with forages during the period of acclimatization.

Processing of Turmeric: 200kg of Turmeric rhizome was purchased and processed as follows: the organic turmeric was first separated from all forms of attached soil, boiled and sliced to increase the surface area. The sliced samples were air dried to reduce moisture content. The dried turmeric was

grounded into powder with an electric grinder and sieved so as to have uniform sizes of powder.

Organic turmeric → boiling → slicing → drying & grinding.

Feed formulation and feeding: feed was formulated for the rabbits in the treatment groups. Turmeric was not included as one of the constituents of the first formulated organic feed but was included in the second formulated feed. Also, 2% turmeric was added to the formulated feed. Garlic, *Asparagus racemosus* and *Moringa oleifera* were included as premix to take care of ethnoveterinary requirement. The rabbits were fed ad-libitum. The feed formulation table and proximate composition of the diet is given below:

Table 1: Feed formulation table

INGREDIENTS (kg)	DIET 1 (No turmeric) %	DIET 2 (turmeric included) %
Maize	18	18
Maize bran	10.8	8.8
Wheat offal	12	12
P.K.C	45	45
Fish meal 72%	2	2
Bone meal	2	2
Oyster shell	1.5	1.5
Salt	0.25	0.25
<i>Moringa oleifera</i>	0.2	0.2
Ginger	0.09	0.09
<i>Asparagus racemosus</i>	0.08	0.08
Turmeric	-----	2

In the table above, turmeric replaces 2% of maize bran. Garlic, ginger and moringa leaf represented methionine, lysine and premix respectively. Honey was used as anti-stress and mixed with water, and *Asparagus racemosus* was included as an anti-biotic.

Animal grouping and treatments

Forty rabbits (40) were allocated into five treatments groups (n=8).

Group A (ttr) - They were fed with formulated organic feed without turmeric inclusion and were not radiated.

Group B (ttR) - The rabbits in this group were fed with organic feed without turmeric and were radiated.

Group C (TTr) - Turmeric was included in the feed of rabbits in this group but were not radiated.

Group D (TTR) - Rabbits in this group were fed with organic feed with turmeric inclusion before radiated.

Group E (control) ttr – Rabbits were fed with commercial feed (growers finisher, ad-libitum and not radiated).

UV Radiation setup

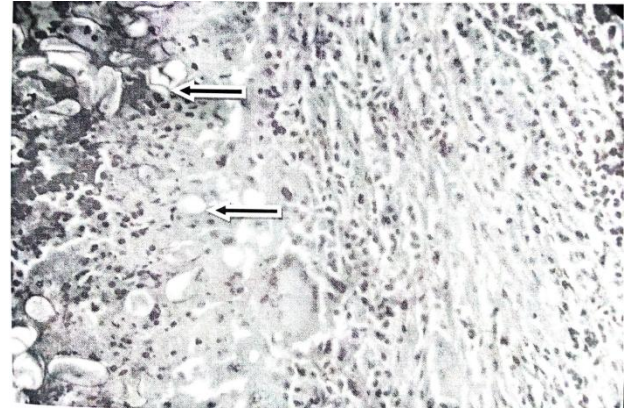
A rectangular wooden radiation box was designed based on established protocol with little modification. A black polythene bag was used to cover the box containing three (3) florescence 30cm long, 66W UV bulb, which was powered by electric voltage. The polythene bag would conserve the heat and prevent the spreading of heat to the cages. The lamp emitted UVB in ranges of 680 to 715nm. At a distance of 20cm, the UV radiation dose was $320\mu\text{W}/\text{cm}^2$ (based on the manufacturer specification).

Mature rabbits within age range 18-20 weeks of group B and D (that are to be radiated) were exposed to UV radiation for 10 consecutive days at 10 minutes period. Experimental procedure was carried out based on the established guidelines for handling and care of laboratory animals and was approved by council on ethical use of animal for research in the institution.

Organ collection- The rabbits were euthanized via cervical dislocation and their liver was harvested, weighed and transferred into organ bottle containing formal saline fixative.

Histology- The liver were dehydrated through varying concentration of alcohol and cleared with xylene. The tissue were subsequently impregnated and embedded in paraffin wax. They were then cut at 3-5 microns, dewaxed and stained with haematoxylin and eosin. The slides were viewed and photomicrographs taken with a digital camera attached to a light microscope.

Result:

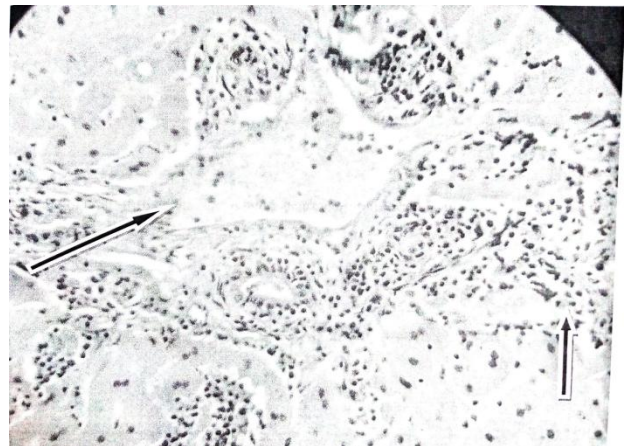


X 400

Figure 1: Photomicrograph of the liver section of Group A

The liver section of Group A rabbits that were fed with organic feed and not radiated reveals a normal histology showing ova cells (black arrows). Meanwhile the ova cells are progenitor cell that are involved in the regeneration process.

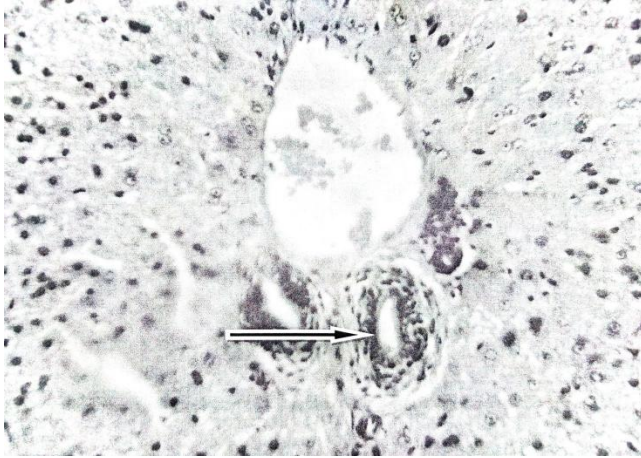
Effect of UV radiation on the liver



X 400

Figure 2: Photomicrograph of Group B (ttR)

The photomicrograph reveals liver section of rabbits radiated and fed organic feed without turmeric inclusion. The liver section shows a dense portal infiltration (black arrow) and lobular extension.

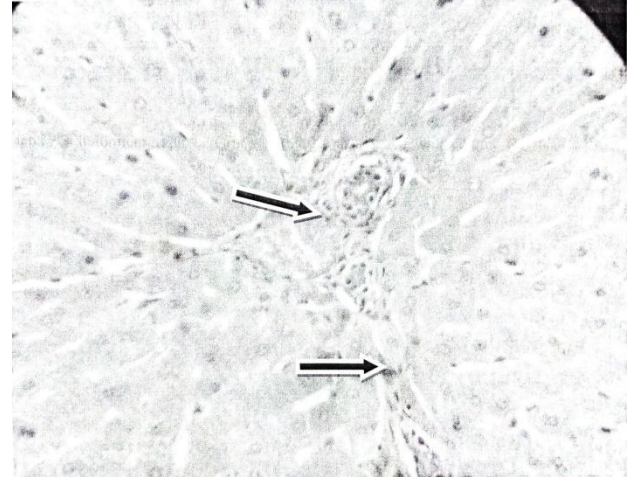


X 400

Figure 3: photomicrograph of the liver section of Group C.

The liver section shows a normal histology with mild portal infiltration (black arrow).

Effect of UV radiation and organic turmeric on the liver



X 400

Figure 5: Photomicrograph of Group E (control)

The photomicrograph reveals normal hepatocyte cell with a well defined cytoplasm, prominent nucleus and nucleolus.

Discussion:

There is a growing evidence that ultraviolet (UV) radiation induces DNA and cellular damage by an indirect mechanism through the generation of reactive oxygen species (ROS)⁸. Histological studies revealed that the group radiated have structural differences compared with the control. The liver section of control group (Group E) fed with commercial feed throughout and not radiated shows a normal hepatic cell with well defined portal triad. Normal histology was also seen in control fed with organic feed without turmeric inclusion and not radiated (Group A). It shows numerous ova cells and granulomatous reaction. Meanwhile, according to Fausto, ova cells are progenitor cell that are involved in regeneration process⁹.

The histology of the liver section of rabbits in group B (that were not fed with feed containing organic turmeric before they were radiated) reveals vacuolar degeneration and focal hepatocyte necrosis which confirms the damaging effect of UV on the liver. Similar effect of liver damage was reported on acetaminophen induced liver damage^{8, 10}.

Furthermore, an essentially normal structure of liver histology was seen in Group C (that were fed with organic feed with turmeric inclusion and not

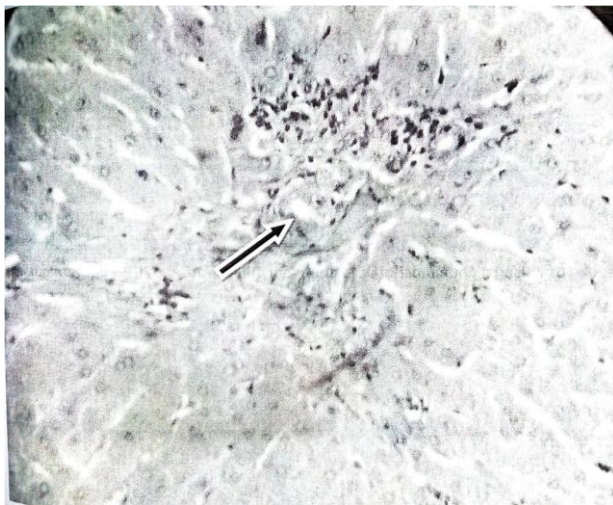


Figure 4: Photomicrograph of the Group D

The liver section of the rabbits that are fed with organic feed with turmeric inclusion before they were radiated shows a mild portal inflammation, (black arrows).

radiated) which confirms the hepatoprotective properties of turmeric. Turmeric hepatoprotective effect is mainly due to its antioxidant properties and its ability to decrease the formation of pro-inflammatory cytokines¹¹.

More so, the histology of the liver section of Group D (that were fed with organic turmeric supplemented diet before they were radiated) shows a mild portal inflammation with normal hepatocyte. This implies that organic turmeric supplemented diet ameliorate the damages caused by radiation on the liver. Also, if the histology of liver section in Group D (that were fed with organic turmeric supplemented diet before they were radiated) was compared to that of rabbits in Group B (that were not fed with feed containing organic turmeric before they were radiated) it was evident that the damages caused by radiation on the liver was more pronounced in Group B than Group D which confirms the hepatoprotective role of turmeric on the liver. This finding was in consonant with the effect of ginger in lead induced oxidative stress^{12,13}.

Conclusion: Above all, this study has shown that Ultraviolet (UV) radiation has a damaging effect on the liver. It causes hepatic necrosis and portal inflammation in the hepatic tissues of radiated rabbits. While the histology of liver section of control group reveals a normal structural integrity. Also, the result correlated with recent findings that turmeric when supplemented with diet has hepatoprotective properties.

Acknowledgment:

We acknowledge Late Professor V.A Togun for his immense contribution and the entire staffs of Physiology Department, Ladoké Akintola University of Technology (LAUTECH) Ogbomosho.

References:

1. Daod H, Aslam J. Source of income from fruits and vegetables paper presented in National workshop on horticultural crops and there important in parkistan. 1996; 1(1):3.
2. Ammon HP, Wahl M. Pharmacology of Curcuma longa. *Planta Med.* 1991; 57:1-7.
3. Kelly DA, Young AR, McGregor JM, Seed PT, Potten CS. Sensitivity to sunburn is associated with susceptibility to ultraviolet radiation-induced suppression of cutaneous cell-mediated immunity. *Journal of Experimental Medicine.* 2000; 191:561-566.
4. Halliday GM. Common links among the pathways leading to UV-induced immunosuppression. *Journal of Invest. Dermatol.* 2010; 130:1209-1212.
5. Kvam E. and Tyrell RM. Induction of oxidative DNA base in human skin cells by UV and near visible radiation. *Carcinogenesis.* 1997; 18(12): 2379-2384
6. Brash DE, Simon JA, Lin A, Mckenna GJ, Baden HP, Halperin AJ, et al. A role of sunlight in skin cancer: UV induced P53 mutation in squamous cell carcinoma. *Pro. Natl Acad. Sci.* 1991; 88(10): 124-128.
7. Kmiec Z. Cooperation of liver cells in health and diseases; advances in Anatomy. *Embryology and cell biology.* 2001; 161: III-XIII.
8. Benneth DC. How to make a melanoma: what do we known of the primary clonal effect? *Pigment cell and melanoma research.* 2008; 21(1): 27-38.
9. Fausto N. Tackling liver progenitor cells. *Natural medicine. Liver parenchyma cells insitu and in primary culture.* *EMBO Journal.* 2005; 2(4): 567-570.
10. Polson J, Fontana RG, Davern TJ, Lalami E, Hynan LS, Schiodt FV. Acetaminophen induced liver failure: Result of a United State prospective study *hepatology.* 2005; 42:1364-1372.
11. Park BK. and Pirmohamed M. The role of cytochrome p450 enzymes in hepatic and extrahepatic human drug toxicity. *Pharmacology and Therapeutics.* 2000; 68(3): 383-422
12. Lisa T. The top 10 antioxidants foods. *Better nutrition, the benefit of antioxidant supplement.* *Journal of Biological sciences.* 2002. p. 34-56
13. Khaki A, Fathiazad F, Nouri M, Khaki AA, Chelar C, Ozanci P, et al. The Effects of Ginger on Spermatogenesis and Sperm parameters of rats. *Journal of Reproductive Medicine.* 2009; 7:7-12.

Disclosure: There was no conflict of interest.